



REGENOTHERAPY®

HISTOLOGY

Prof. G. Papaccio

and His Equipe

Regenotherapy - Histology

University: "Federico II" - Naples



1

Seconda Università' degli Studi di Napoli
Azienda Universitaria Policlinico
Dipartimento di Scienze Medico-Legali
Ambulatorio di
Elettromiografia Clinica applicata alla Medicina Preventiva e Legale
Responsabile: Prof. Bartolomeo Valentino

Sede: Istituto di Anatomia - via L. Armanni 5 - 80138 Napoli - tel. 081.297659 - fax 081.5666010

**Effects of modulated and serial radiofrequencies on osteocyte and
epidermal hair growth: an immunocytochemical study.**

Prof. Gianpaolo Papaccio*,

*Department of Public Medicine, Section of Human Anatomy, School of Medicine,
2nd University of Naples, 5 via L. Armanni, 80138 Naples (Italy);

Running title: radiofrequencies and growth.

ADDRESS FOR CORRESPONDENCE: Prof. Gianpaolo Papaccio

FAX +39 081 566 60 14

E-mail: gianpaolo.papaccio@unina2.it

Key words: Regenotherapy, radiofrequencies, osteocyte, epidermal hair, growth.

ABSTRACT

This study has been performed on rats subjected to radiofrequencies using a "REGENOMED" (Omnia Xenion SA, Switzerland, Lugano). The results have demonstrated that treated rats presented with a significant higher cellular proliferation rate with respect to untreated. This was evidenced both in epidermis and in osteocytes. The method seems to be quite interesting in view of its use for cellular proliferation rate increase, both in many instances.

INTRODUCTION

Over the past years a novel technique, based on the use of radiofrequencies, has been developed and used in many therapies (Pathologies). Actually, the role of this therapy in cellular growth is, up to now, unknown.

The said therapy is already available by using the device "REGENOMED" (Omnia Xenion SA, Switzerland, Lugano). Application of such a method include dental pathologies and rehabilitation (Utilization) and has been presented as a regenerative therapy. This led us to verify the possible action of said radiofrequencies upon tissue and cell growth.

It is well known that epidermal cells and, particularly, hair cells show an high percentage of growth, while osteocytes are cells showing a rather slow percentage of growth and regeneration. Therefore, we have pointed our attention to these two cytotypes in order to better understand the capability of the radiofrequencies to activate cellular proliferation.

We started the study using Wistar rats. Up to now, we have observed that regenotherapy, which is based on the use of serial and modulated radiofrequencies, is able to significantly stimulate the growth and proliferation of both epidermal hair cells and osteocytes.

MATERIALS AND METHODS

Animals: Adult Wistar rats, of both sexes, were maintained in the Second University facility. Animals, weighing 400 to 450 g each, had free access to water and food.

Experimental procedure:

Animals, belonging to control (group 1) and treated (group 2) groups, were subjected, two hours before a surgical intervention, to the intraperitoneal injection of undiluted labeling reagent (1 ml/100 g b.wt.) of a cell proliferation kit (anti-5-bromo-2'-deoxyuridine/nuclease monoclonal antibody, RPN 20, Amersham Pharmacia, Little Chalfont, UK). Then animals, under ether anaesthesia, were subjected to a surgical preventive ablation of a 0.5 square centimeters of dorsal epidermis and of a 0,1 square centimeters of the right gonion mandibular bone. These surgical ablations were done each on a different animal.

After the surgical intervention, each animal was kept in a different cage. Rats belonging to group 2 (treated animals), were subjected to the regenotheapy treatment. This consisted in the use of a Regenomed equipment (Omnia Xenion SA, Switzerland, Lugano), which emits radiofrequencies from 0 to 400 mHz. Each cage was covered with flat aerals made by the manufacturer. Emissions were set up for 20 min per day and for a total of 20 days of treatment. At the end of the treatment animals were left without emissions for 10 days and, then, sacrificed, together with control group animals, which were not subjected to the radiotherapy.

At the sacrifice time, from each animal both epidermis and mandibular gonion were excised at the same level of the surgical ablation. The excission was of 1 cm squared. Tissues were immediately kept and fixed in Bouin's liquid and embedded in paraffin.

Ex-vivo immunocytochemistry: Immunocytochemical observations were made ex-vivo on pancreata taken from the animals. *In vivo* pulse labeling with RPN 20 (5-bromo-2'-deoxyuridine) (BrdU, Amersham Pharmacia, Little Chalfont, UK), a thymidine analogue, and immunostaining of the incorporated BrdU were used to mark the cells that had synthesized DNA during the incubation time.

Two hrs before killing, RPN 20 (100 mg/Kg b. wt., freshly dissolved in PBS) was injected i.p. into the treated animals. After killing under anaesthesia, tissues were kept from animals and fixed in 4% paraformaldehyde. The number of immunostained nuclei was quantified.

Cell proliferation measurement: Cell proliferation was measured by the 3-(4,5-dimethylthiazolyl)-2-5-diphenyl-2H-tetrazolium-bromide (MTT) assay. Cells were seeded in a gelatin-coated 96-well plate at a cell density of 10^3 cells/well. Cells were grown in RPMI 1640 containing 20% FCS plus 100 μ g/ml ECGS (Sigma, Milan, Italy). After 1, 3, 5 and 7 days of culture cells were incubated with the MTT solution (0.5% 50 μ l/well) for 4 h.

During this incubation period, a water-insoluble formazan dye is formed. After solubilization, the formazan dye is quantitated using a scanning multiwell spectrophotometer (ELISA reader) at 570 nm. The absorbance revealed directly correlates to the cell number.

The results were expressed as optical density at 570 nm. Cell proliferation rate was compared to that of the same cell belonging to untreated animals.

The intensities of the bands were quantified in an Ultrascan XL Enhanced Laser densitometer (LKB, Bromma, Sweden) and expressed in arbitrary units of optical density (OD).

Statistical evaluation:

Data were computed as means \pm SD and compared using Student's *t*-test for paired or unpaired samples, as appropriate.

RESULTS

Cell proliferation capacity: Proliferation rate of epidermal hair cells and osteocytes was quantified by BrdU specific ELISA method. Significant cell proliferation was observed in the examined samples. MTT assay reveals that epidermal hair cells show a proliferation capacity which was higher with respect to osteocytes ($p < 0.01$) as well as with respect to controls ($p < 0.001$) (Figs) ; on the other hand also osteocytes presented with a proliferation ability significantly higher than that of controls ($p < 0.001$) (Figs).

The results have also demonstrated that in untreated animals the proliferation of osteocytes is quite absent and that of epidermal cells is significantly less intense.

DISCUSSION

The present study has been performed using a novel technique, based on the use of radiofrequencies. The role and efficacy of this therapy in cellular growth is, up to now, unknown. The device "REGENOMED" (Omnia Xenion SA, Switzerland, Lugano) is already available and application of such a method include dental pathologies and rehabilitation and it has also been presented as a regenerative therapy.

On the other hand, it is well known that epidermal cells and, particularly, hair cells show an high percentage of growth, while bone cells, i.e. osteocytes, are cells which show a rather slow percentage of growth and regeneration. Therefore, the aim of the present study was to point our attention to these two cell types in order to understand the ability of the radiofrequencies to activate cellular proliferation.

The study has been performed using Wistar rats. The results have clearly demonstrated that regenotherapy, which is based on the use of serial and modulated radiofrequencies, is capable to significantly stimulate the growth and proliferation of both epidermal hair cells and osteocytes. In particular, the cell proliferation rate of epidermal cells has been found quite higher than that seen in untreated controls.



**SECONDO ATENEIO DI NAPOLI
FACOLTA' DI MEDICINA E CHIRURGIA
DIPARTIMENTO DI MEDICINA SPERIMENTALE
ISTOLOGIA ED EMBRIOLOGIA**

via Luciano Armanni, 5 – 80138 NAPOLI
Tel. # 081-5666014\15 Fax # 081-5666014
E-mail: gianpaolo.papaccio@unina2.it

*Prof. Gianpaolo Papaccio
Professore di ruolo di Istologia*

Napoli li 8 Aprile 2002

Oggetto: ricerca in corso su ratti sottoposti a regenoterapia.

Dalle ricerche, ancora in corso, si è evidenziato chiaramente sinora che la regenoterapia non ha alcun effetto di tipo secondario su altri organi non selezionati per la preventiva "ingiuria" chirurgica.

In particolare i testicoli di ratti maschi sono risultati perfettamente nella norma ed assolutamente integri così come i controlli.

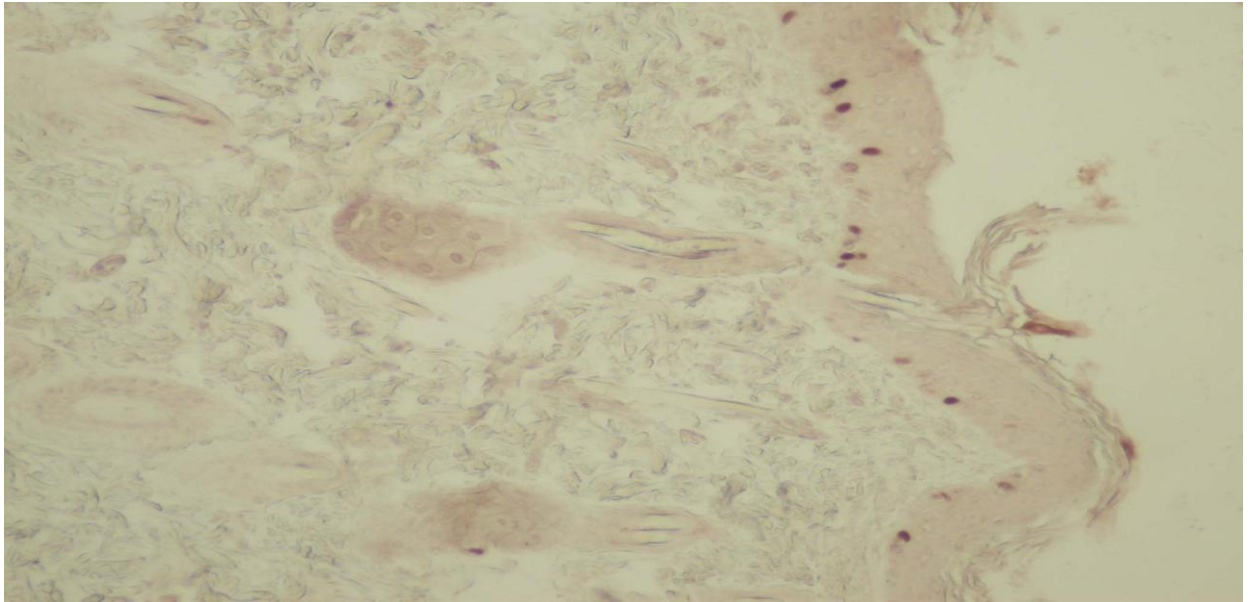
Nessun effetto è pertanto stato osservato sulle gonadi né sugli elementi delle linea germinativa di tali animali.

In fede

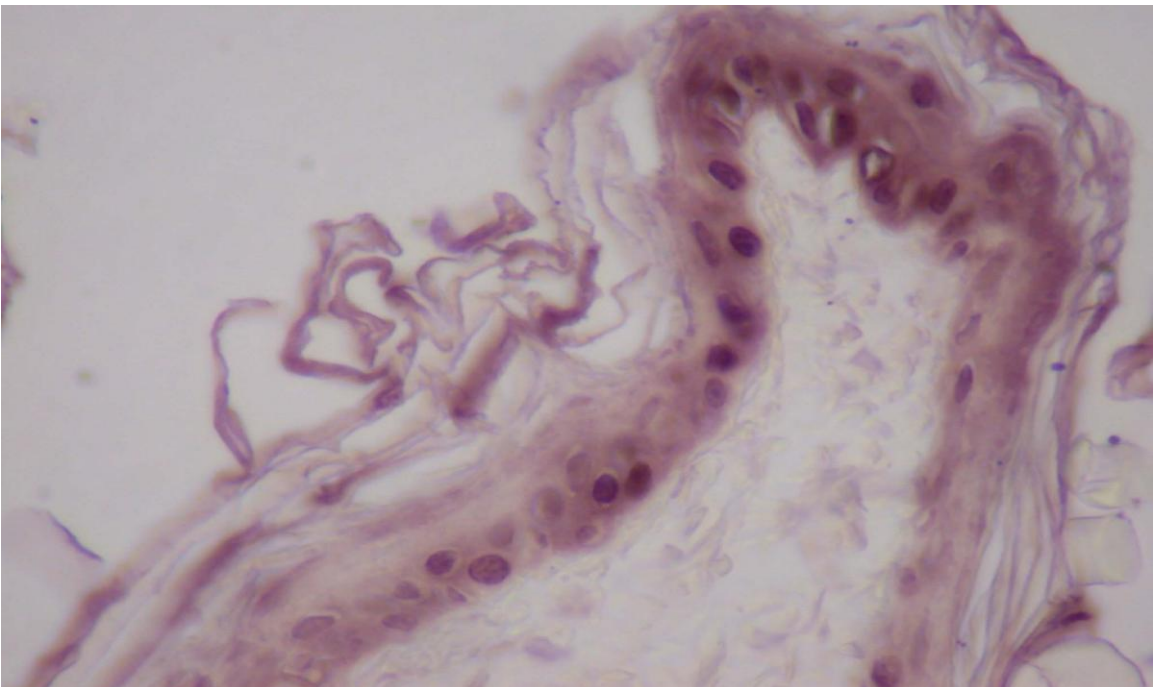
Prof. Gianpaolo Papaccio

Control after 4 days. (upper lip)

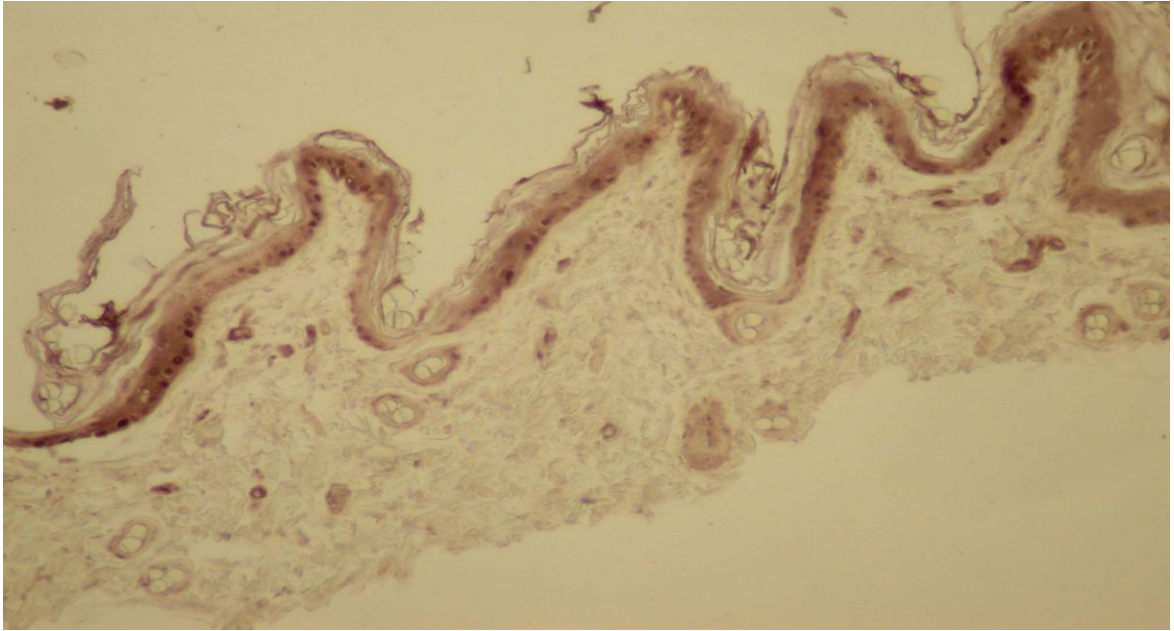
Rats not treated with Regenotherapy, but only under BrDu control; visible only few cells of the epidermis basal layer.



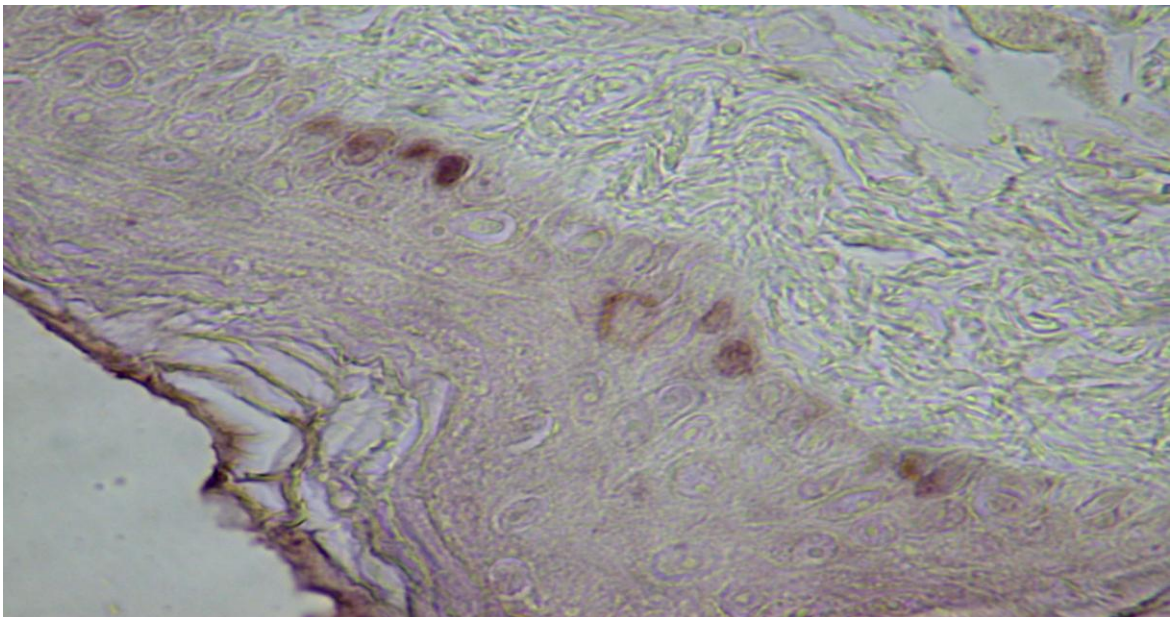
Epidermis after 4 Regenotherapy applications. (enlargement -40x): Same conditions of slide n. 3, but with more optic enlargement.



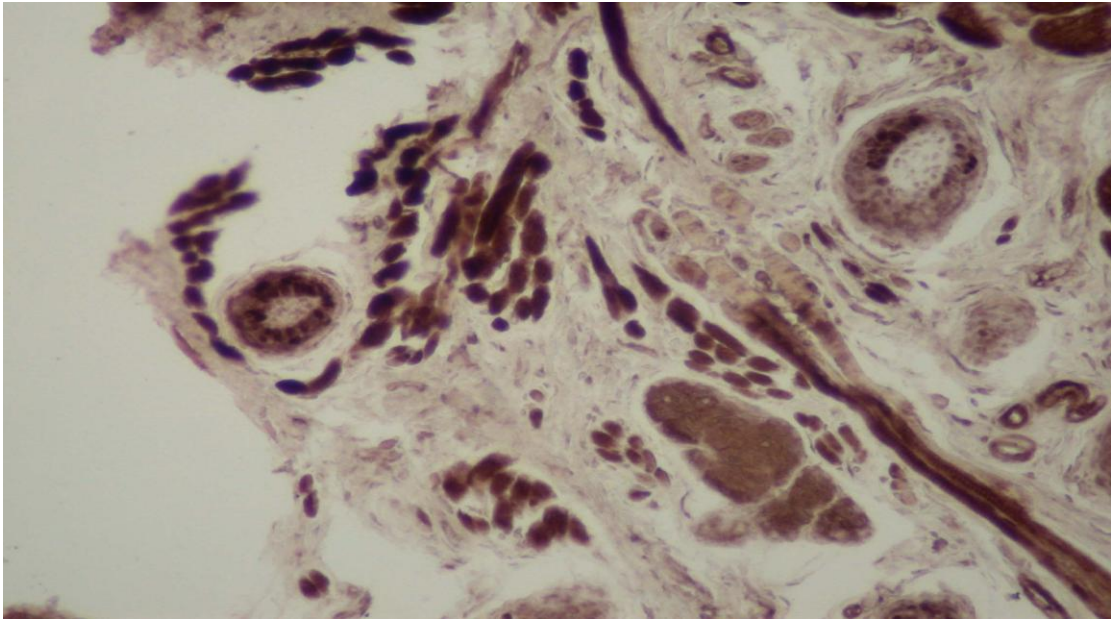
Epidermis after 4 days: evidence of intense colouring of the epidermic basal layer (upper lip) in rats treated for 4 days (one application per day) with Regenotherapy.



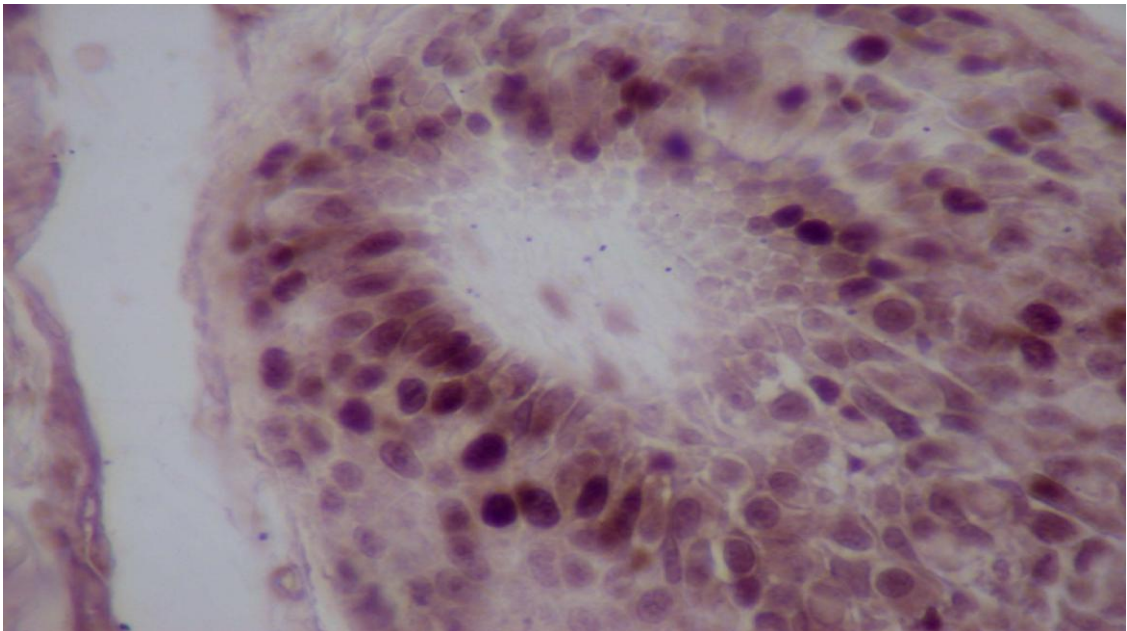
Epidermic control n. 6: same evaluation as slide n. 2, more enlarged.



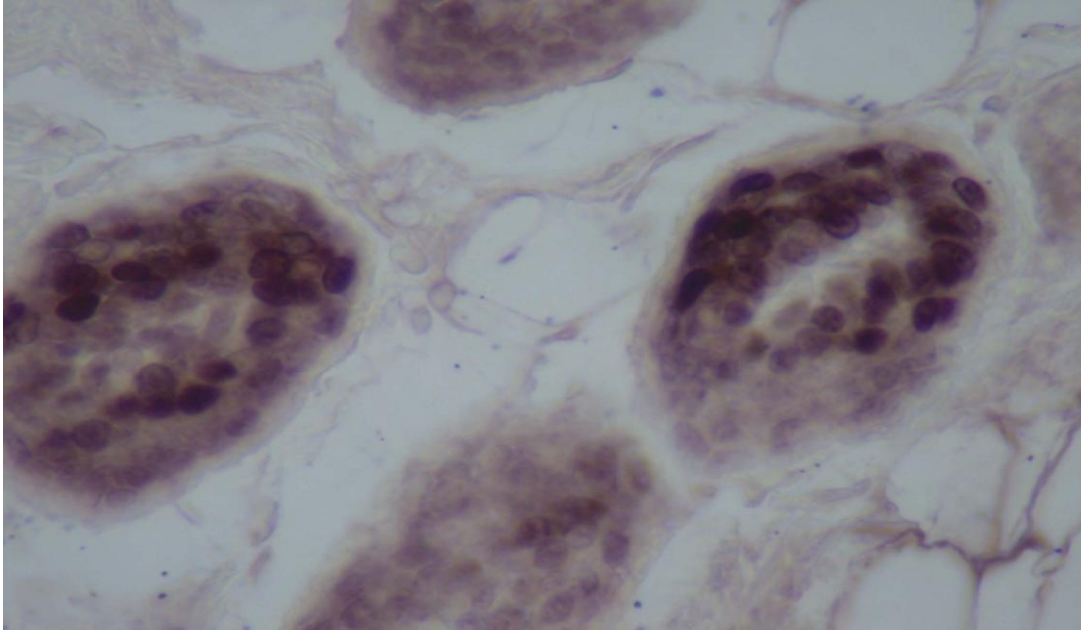
Upper lip, hair and muscles: evidence of more colouring of cells of the hair bulb and muscular fibrocells matrix. (four Regenotherapy applications)



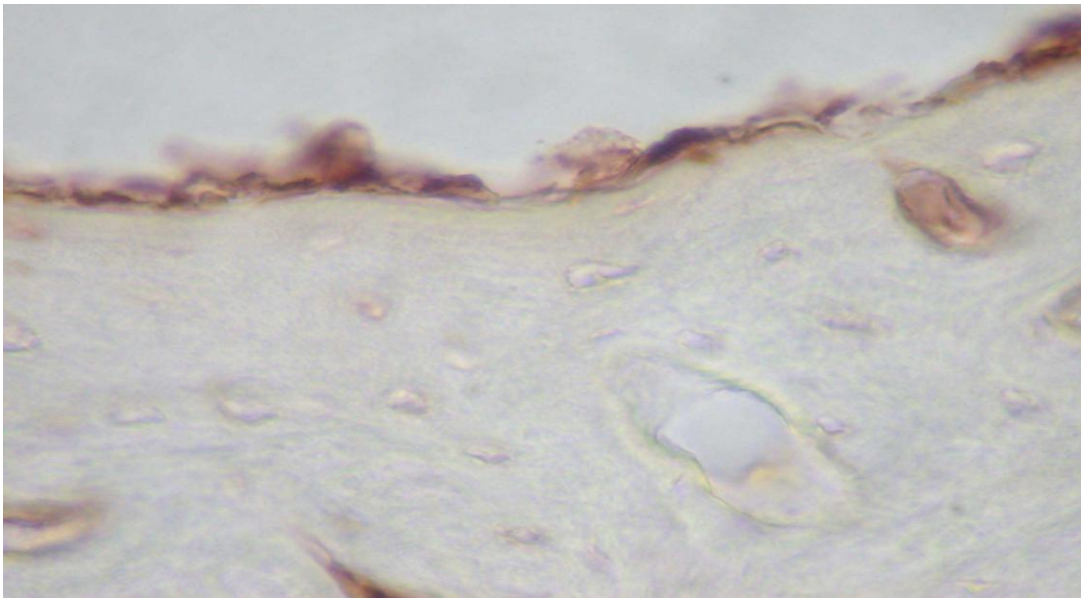
Upper hair lip matrix: matrix section of upper hair lip. It can be seen an intense cellular proliferation after 4 Regenotherapy applications (one per day).



Upper hair lip fig. 2
Evidence cellular proliferation at the hair bulb base.
Number 4 Regenotherapy Applications. (one per day)

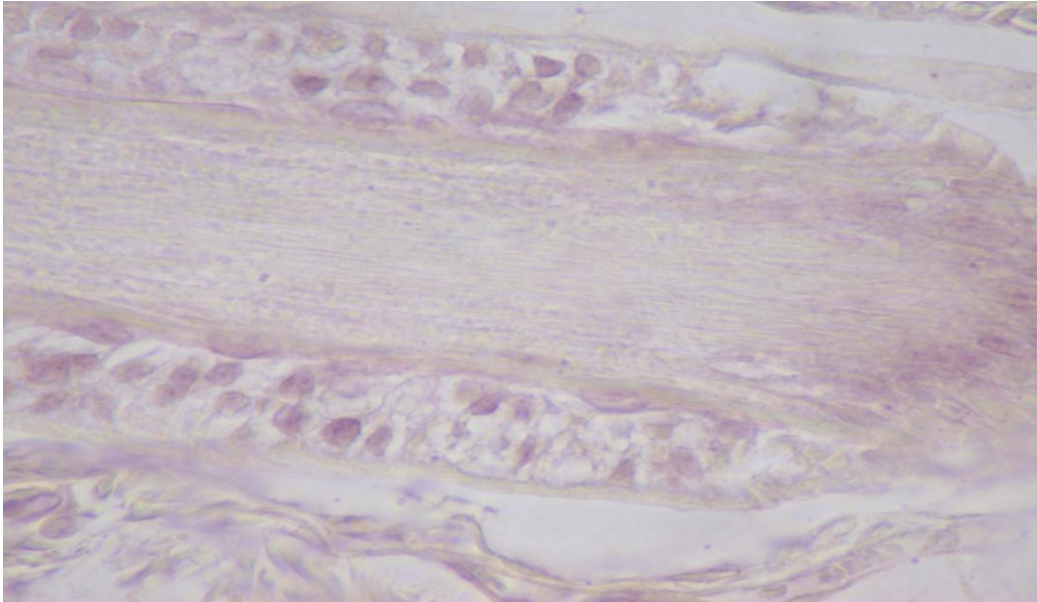


Bone and periosteum after 4 Regenotherapy applications (one per day).



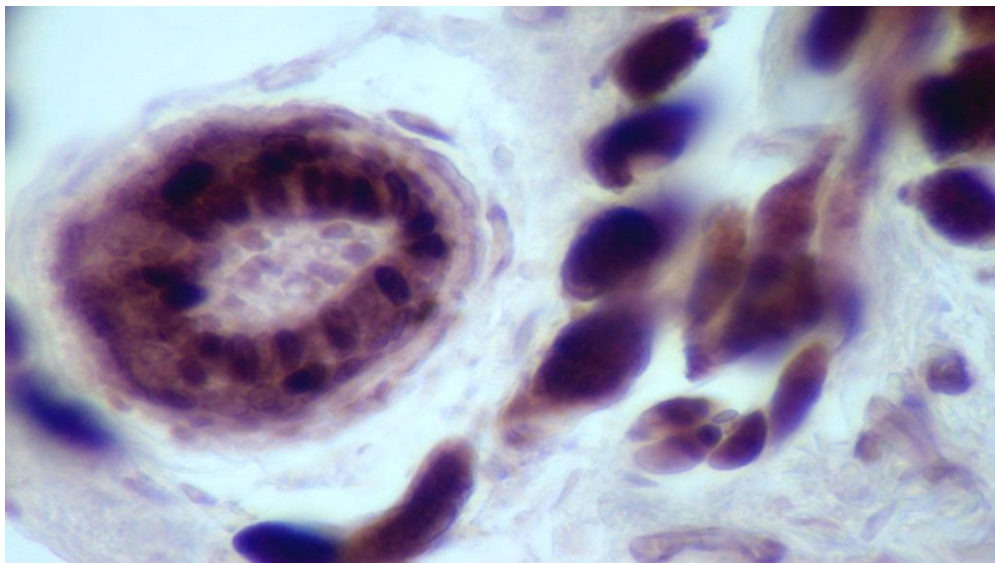
Epidermic hair control n.3

Longitudinal hair section, with weak evidence of BrDU reaction, with out Regenotherapy application.



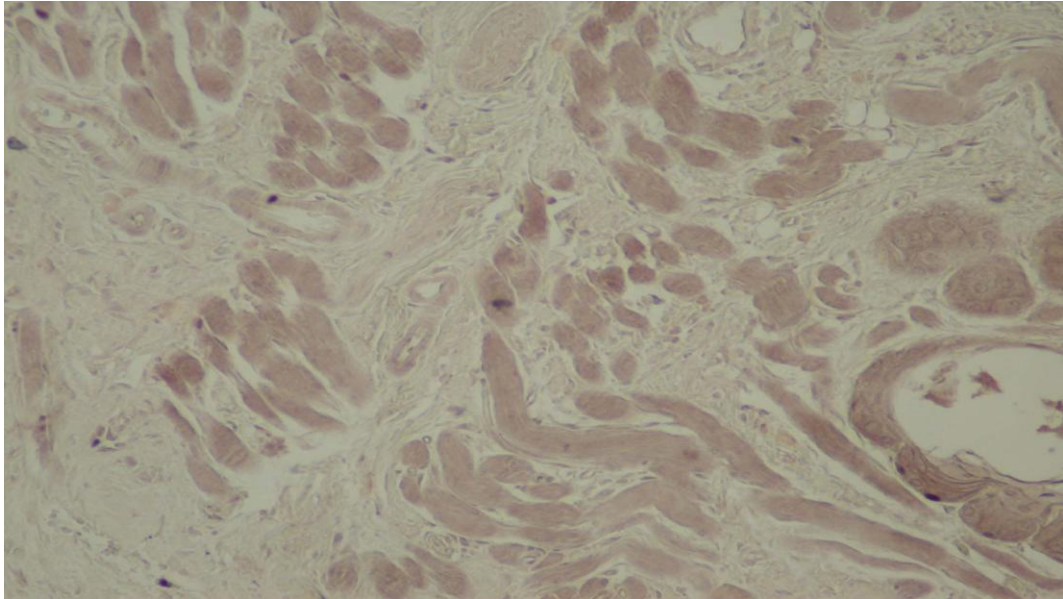
Upper lip hair.

Prominence evidence of cellular proliferation, in the picture enlargement of the hair bulb of the upper lip. After 4 Regenotherapy applications.



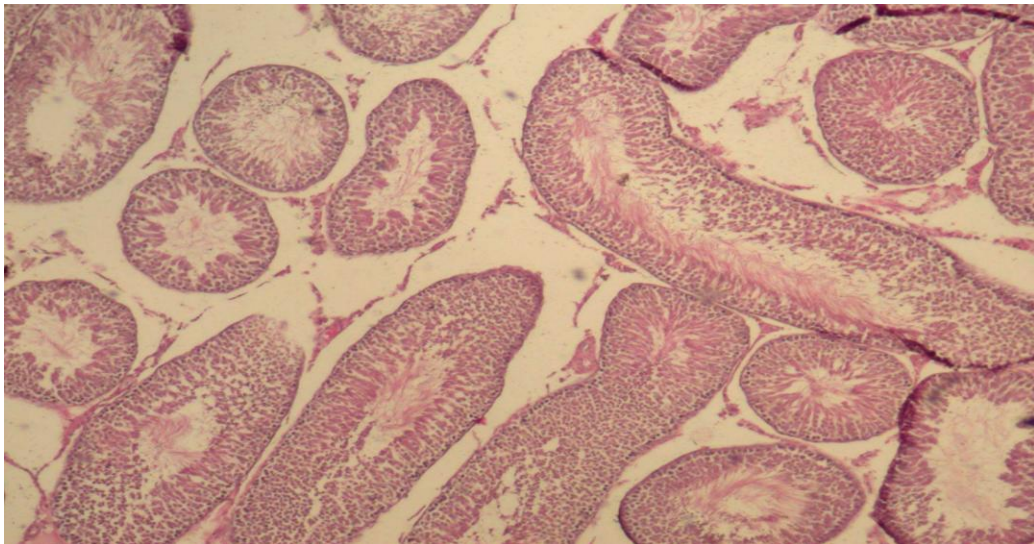
Muscular control 4 days.

Weak chromatic prominence at the BrDU reaction; results obtained with no Regenotherapy applications.

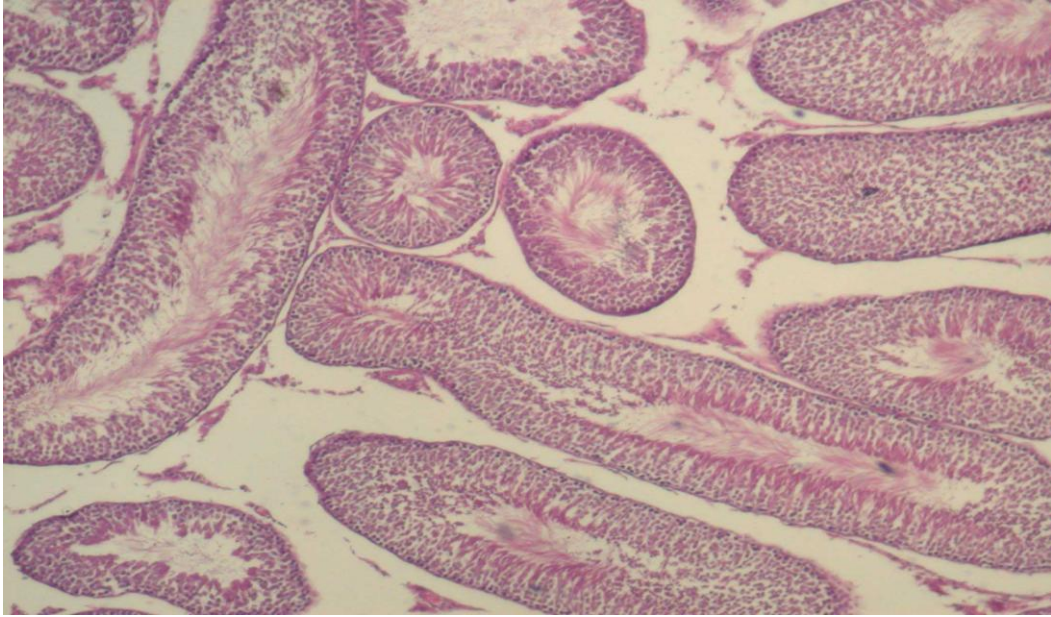


Testicle not treated.

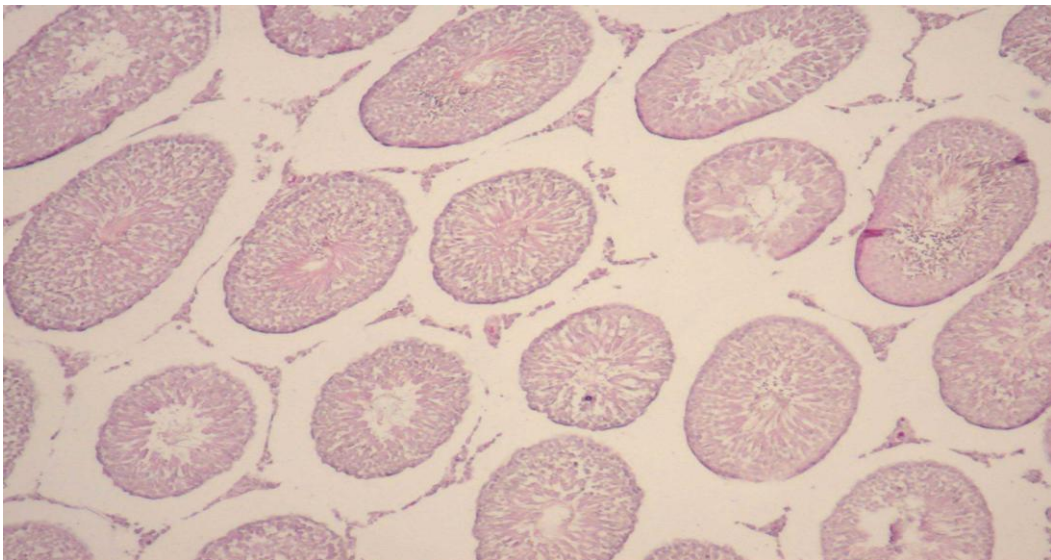
The testicle seminal ducts of a rat not treated with Regenotherapy. Results: normal istological picture.



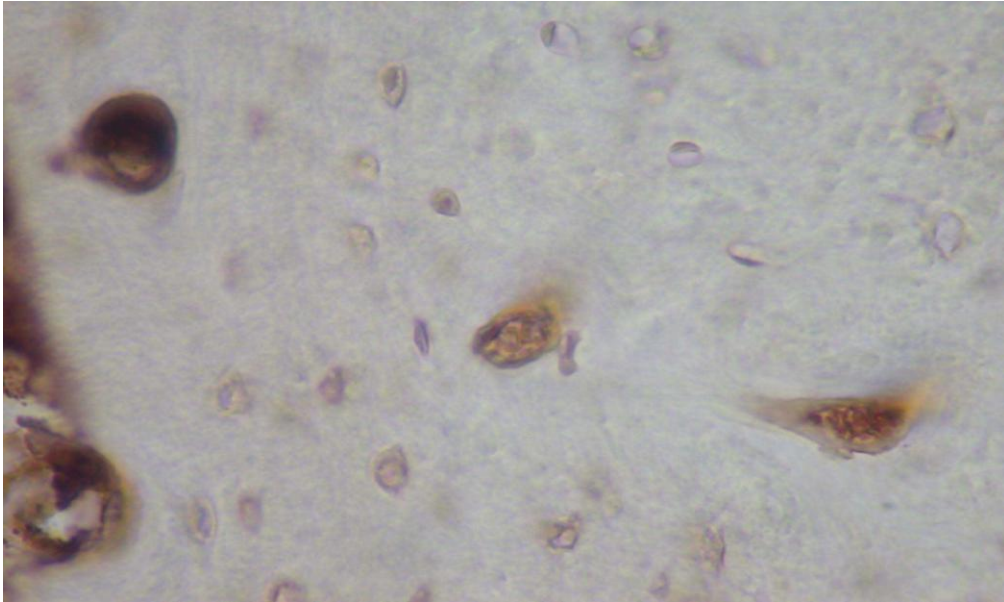
**Testicle after 30 days of Regenotherapy applications.
Rat seminal ducts after 30 Regenotherapy applications (one per day).
Results: normal istological picture.**



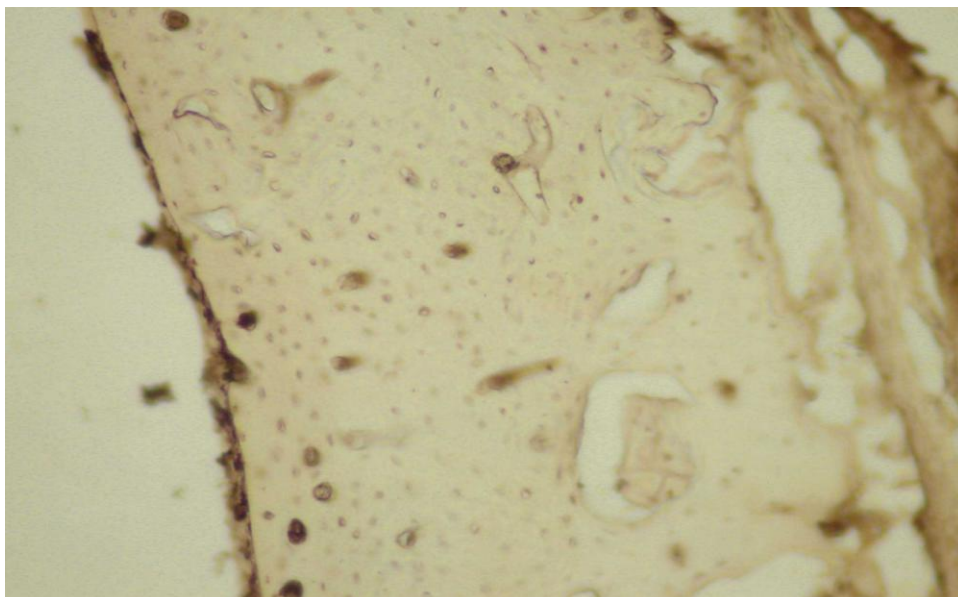
**Testicle after 30 days of Regenotherapy applications.
Same conditions as slide n.13**



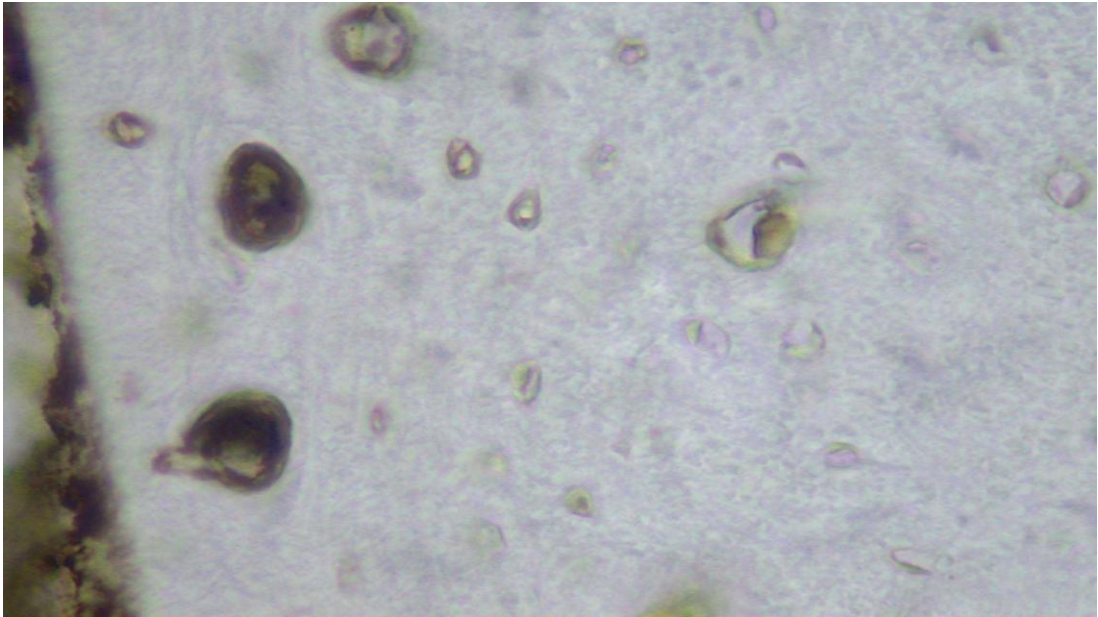
Bone after 4 Regenotherapy applications. Image JPG
Visible osteomas, very big and other smaller, evidence of osteocytes nucleus from BrDU reaction after Regenotherapy treatment.



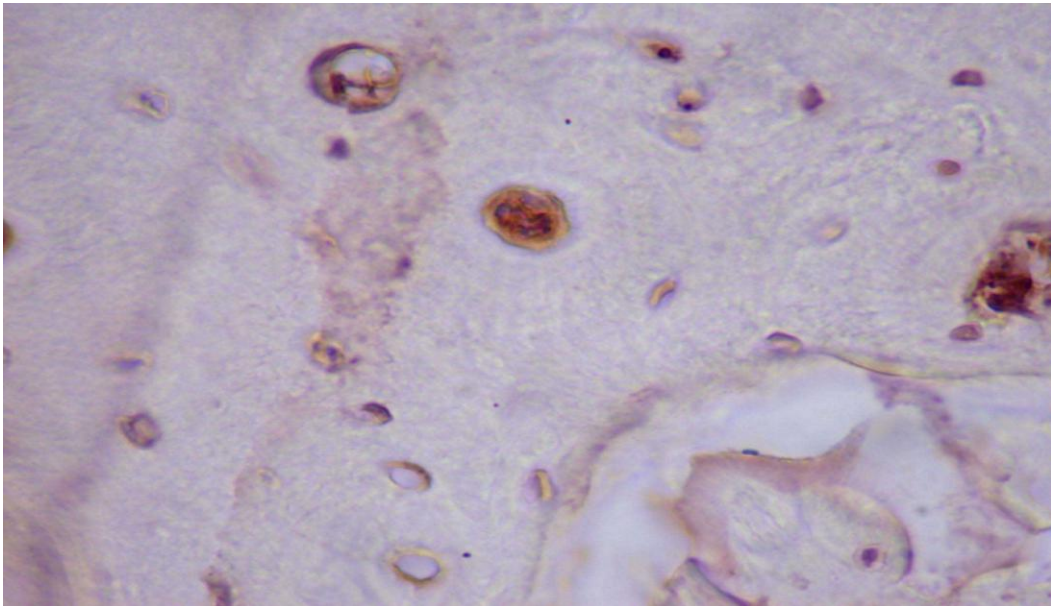
Bone after 4 days (one application per day). Image n. 3. A numerous osteomas ar visible with nucleus of endostal cells. Some Havers chanals are cut in longitudinal sense. Presence of periosteum (left side) with nucleus of cells of changes layer (osteocytes progenitor) intense coloured results.



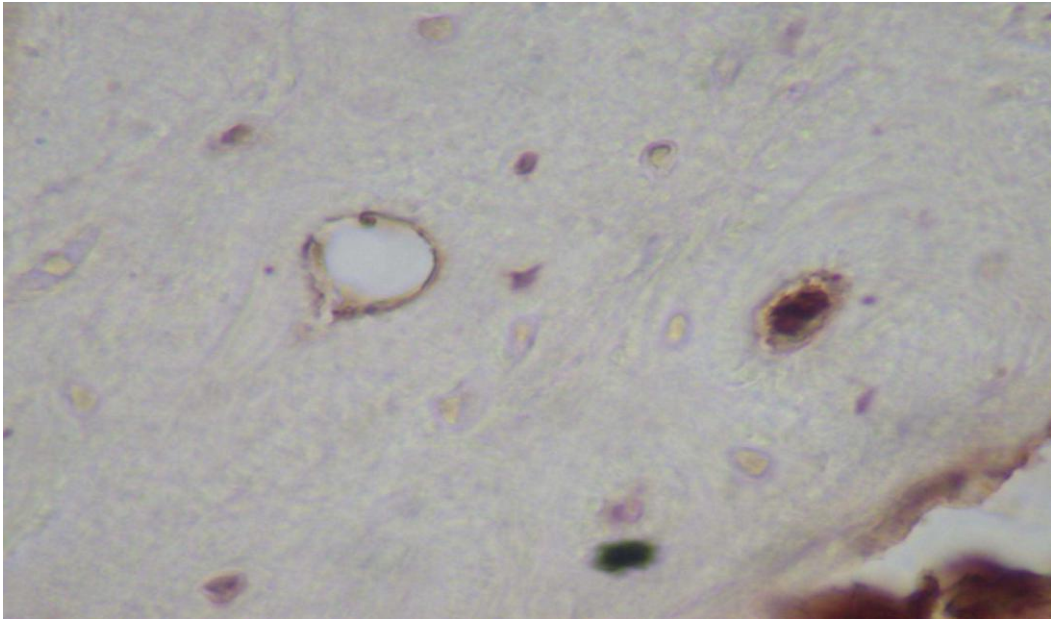
**Bone after 4 applications of Regenotherapy. Image n. 5
same considerations as image n.1.**



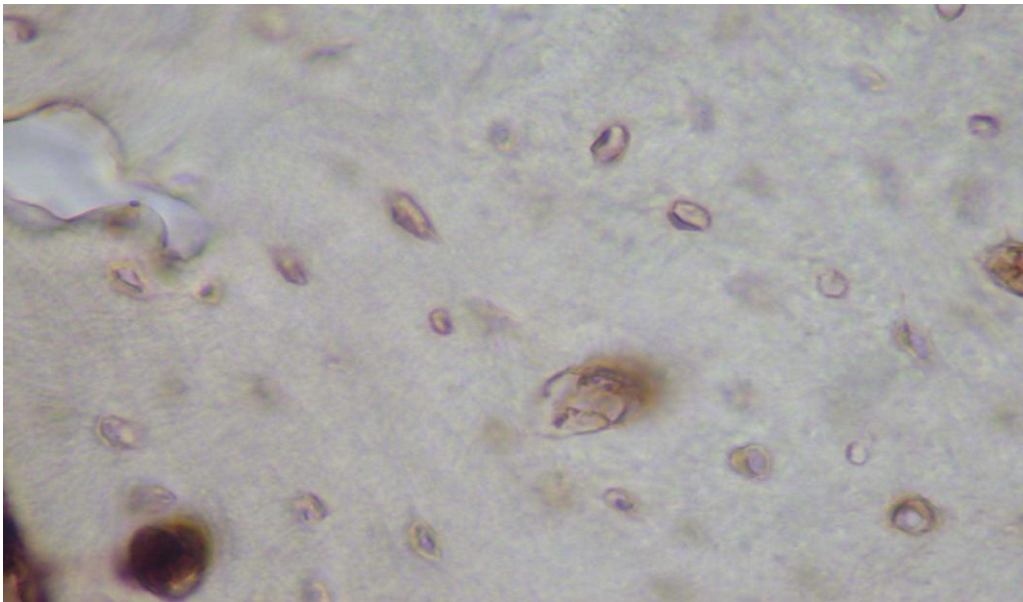
Bone after 4 Regenotherapy applications. Image n. 6



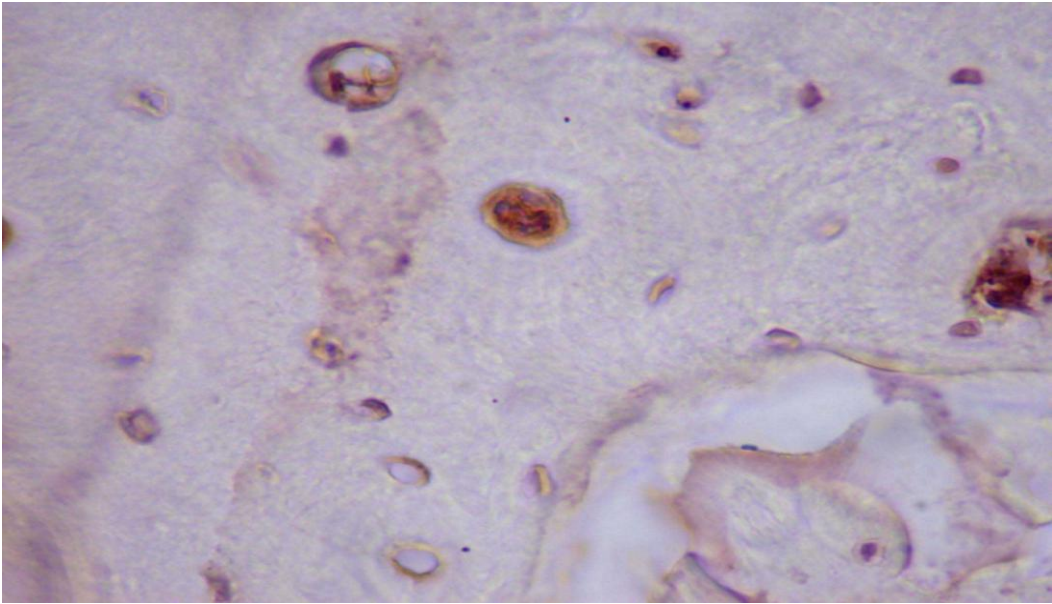
Bone after 4 Regenotherapy applications. Image n. 8



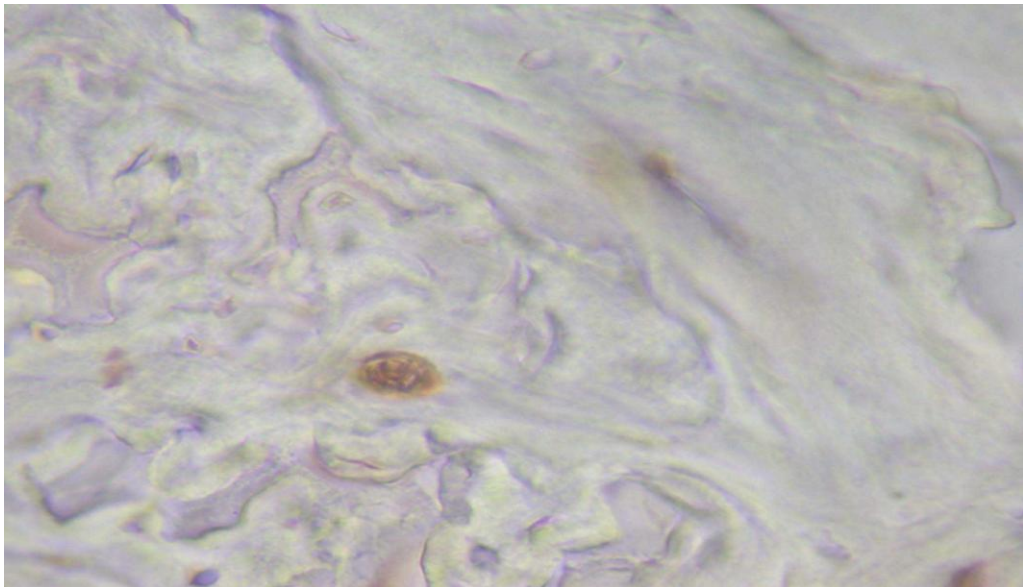
**Bone after 4 Regenotherapy applications. Image n. 2 JPG.
Same reference as image n.1.**



Bone after 4 Regenotherapy applications. Image n. 7
Visible 4 big harvesian ducts, with endostal cells and a lot of smaller chanel, with an intense coloration of osteocytes.

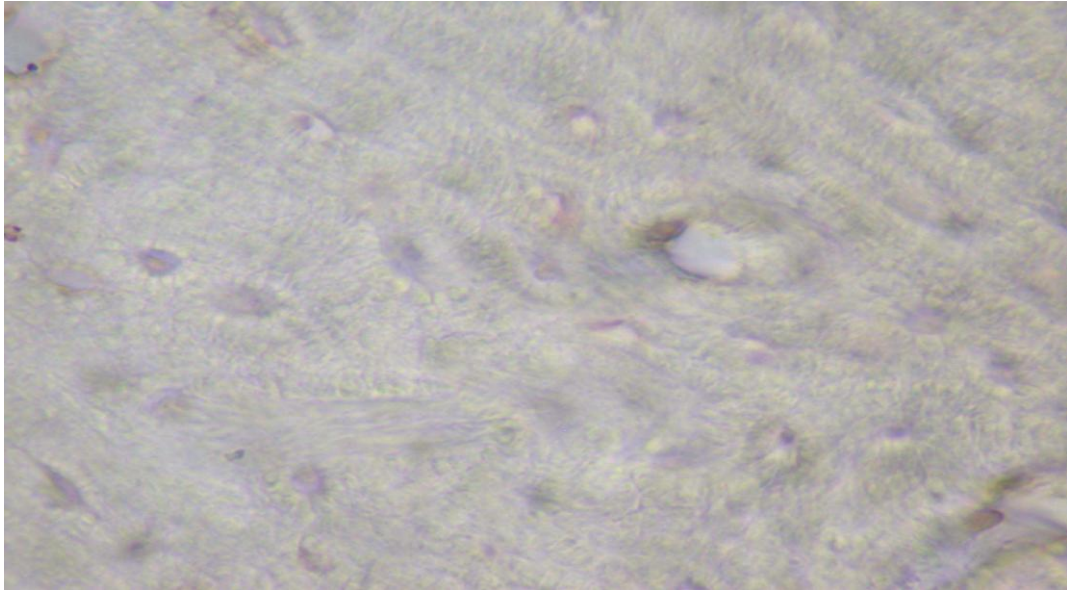


Bone after 4 Regenotherapy applications. Image n. 9.



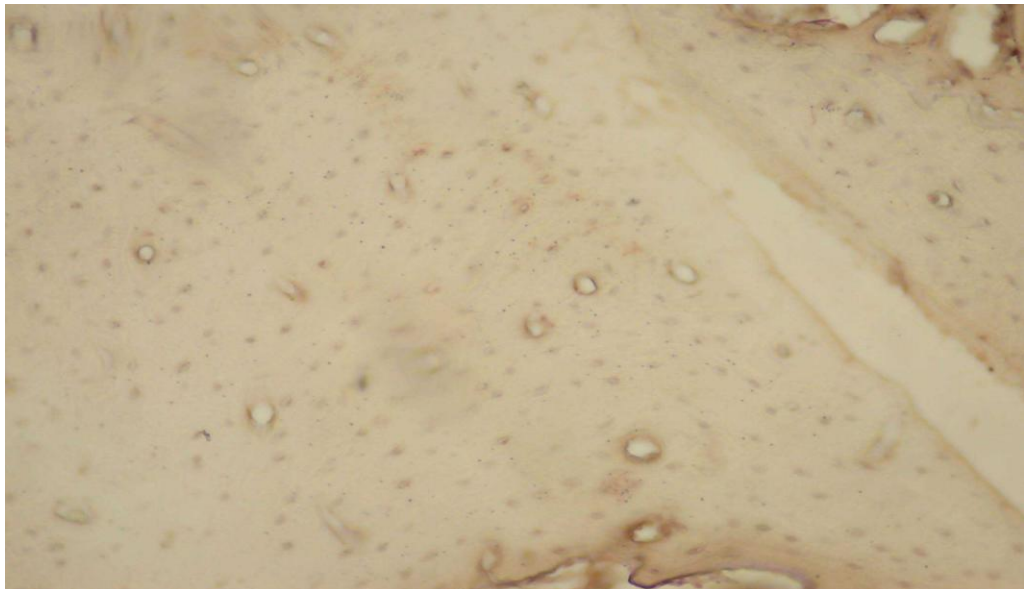
Bone after 4 days. Control n. 1.

Numerous osteomas, a large one to be noted at the center of the image. A weak result of nucleus coloration.

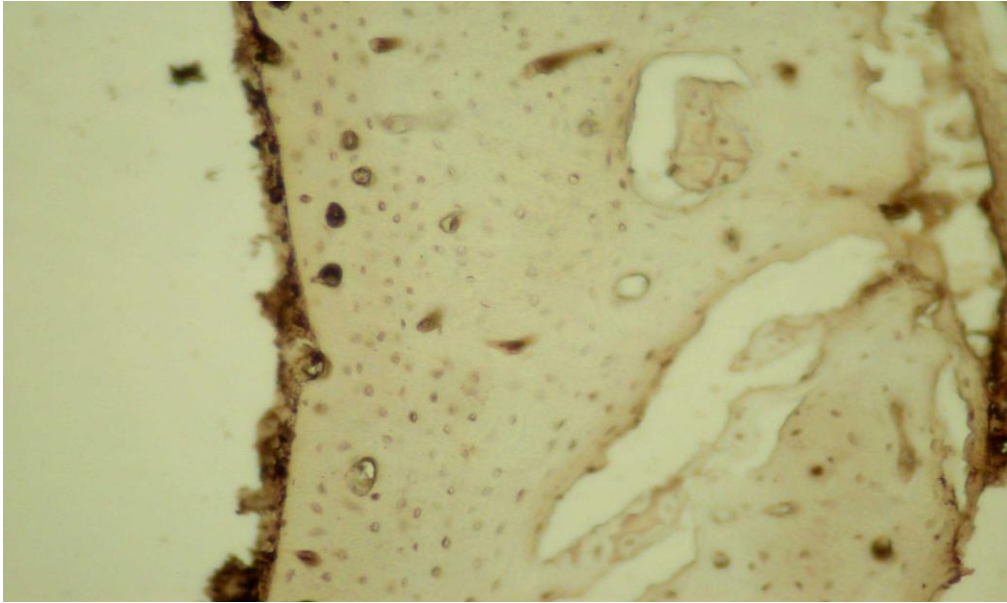


Bone examination after 4 days. Image n. 2.

Numerous osteomas. Scarce reactive coloration of the BrDU.



**Bone after 4 Regenotherapy applications. Image n. 4.
Same considerations of image n. 3.**



**Bone examination after 4 days. Image n.3.
Scarce visibility of osteomas. Weak nuclear coloration.**

